

Skin Ultrasound

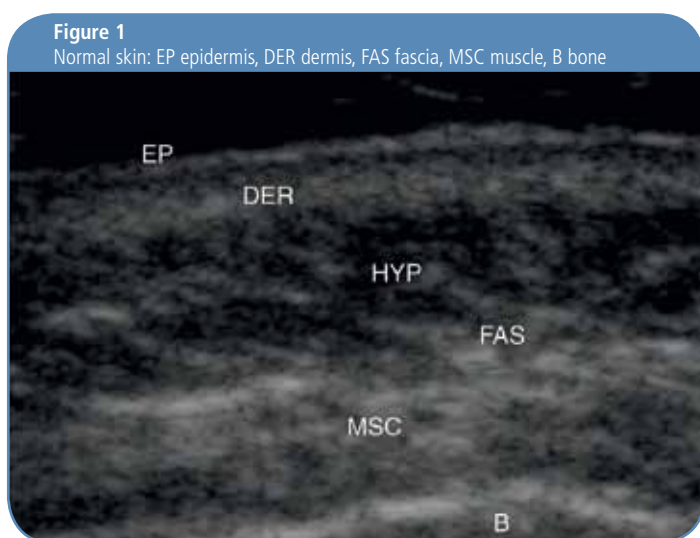
Where MHz can make a difference



“Thanks to the available very-high-frequency (up to 22 MHz) in Ultrasound technology it is now possible to examine benign and malignant skin lesions in epidermis, dermis and subcutis as well as blood vessels close to the skin. Precise measurement of skin thickness and accurate assessment of internal skin structures also supply better answers regarding the performance of surgical or non surgical procedures, therapeutic or cosmetic treatment and follow up”

Dr. Fernando Alfageme, Dermatology Associated Professor at the Universidad Autónoma de Madrid, Spain

Most dermatologists are not fully aware of the many useful possibilities that ultrasound offers in the clinical practice. Here are some examples of its practical applications sorted by skin pathology as well as a short overview of how ultrasound works along with a description of which devices are suitable for skin ultrasound (Fig. 1).



Inflammatory skin diseases

Regardless of the cause producing echogenic effects, ultrasound characterises inflammatory skin diseases with the following features:¹

- **view of a subepidermal hypoechoic halo displaying a papillary dermal edema**
- **local blood flow increase, displayed by increased Doppler signal**
- **homogenization of cellular tissue in the event of subcutaneous cellulites or an usual reversed response to ultrasound, hypoechoic lobules become hyperechoic and hypoechoic walls become hyperechoic.**

Ultrasound allows us to determine to what extent bacterial skin infections have spread to deeper skin layers (fasciitis, osteomyelitis)² and to detect and guide abscess drainage.

This technique allows us to detect hyperkeratosis within the epidermis, inflammation of the underlying tissue as well as increased

blood flow in viral warts³ and these parameters can be viewed and measured to guide us in selecting the most appropriate treatment also in the event of persistent viral warts.⁴

Detecting the inflammatory stage or the inactive/scar stage of skin inflammations produced by autoimmune diseases is crucial to determine patient's treatment. During the inflammatory stage, lupus or morphea⁵ plaques exhibit inflamed skin characteristics (epidermal dermal interface hypoechoogenicity, coupled with increased local blood flow Doppler measurements) while during the scar stage you will witness dermal and hypodermis hyperechoogenicity due to sclerosis and panniculus decrease with fat atrophy.

Ultrasound detects inflammatory skin characteristics along with hyperkeratosis also for psoriasis.⁶ Inflammation's response to treatment can be measured based on this ultrasound data to quantify specific, systemic and organic drugs response.⁷

Skin Cancer

Ultrasound provides us with information regarding malignant tumours and benign lesions' penetration as well as the involvement of secondary structures and/or locoregional metastasis. Ultrasound increases sensitivity and specificity of subcutaneous benign tumours' clinical diagnostics.⁸

In the event of malformations and vascular tumours, ultrasound allows us to differentiate lesions with increased blood flow from those with low blood⁹ flow thereby allowing us to adjust the initial diagnosis.

Ultrasound supports clinical diagnosis and local staging of epithelial tumours, helping us detect tumour borders for complete excision or according to Mohs' surgery.¹⁰

It is also useful to monitor cryotherapy¹¹ or photodynamic therapy treatments, as well as epithelial neoplasms¹² early recurrence.

The usefulness of ultrasound to evaluate and follow-up melanoma is widely recognized to the extent that some teams regard its use as routine.¹³ Ultrasound differentiates melanomas with a Breslow thickness greater than one mm¹⁴ and enables early detection of metastases regional sites. For widespread pathologies, ultrasound is also useful to measure melanoma metastasis¹³ response to chemotherapy (Fig. 2).

Figure 2 Amelanotic melanoma. Melanoma's hypoechoic and homogenous appearance as well as the extensive neovascularization it has induced is clearly displayed by the ultrasound

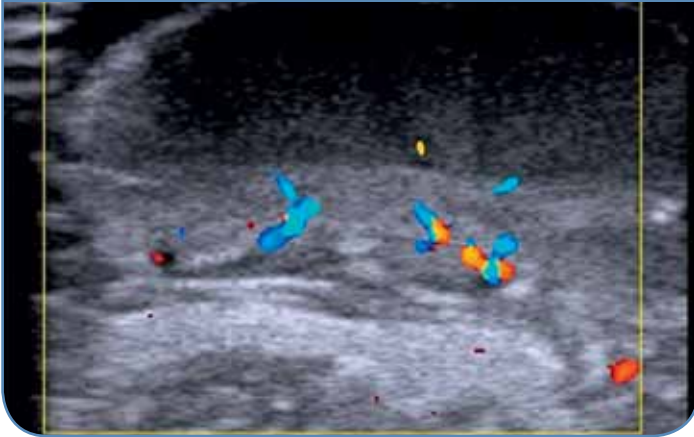
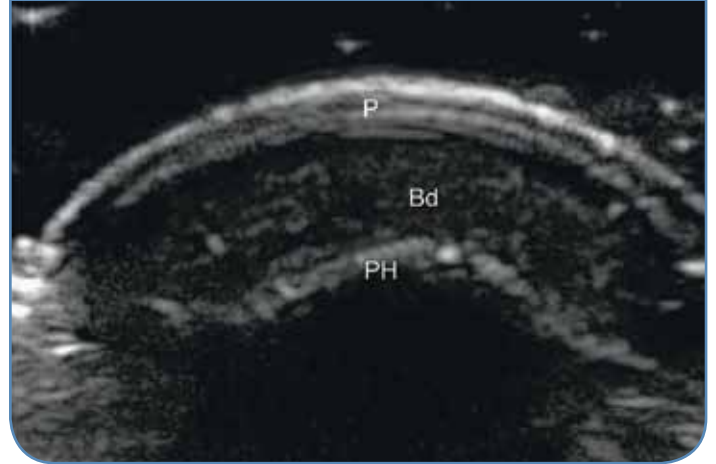


Figure 3 Normal nail (crosscut) P nail plate, Bd nail bed, PH distal phalanx



Nail diseases

The evaluation of nail's health conditions with skin ultrasound allows us to observe pathologies that are located under the nail plate without the need to surgically remove it¹⁵ and to quantify subungual exostosis and nail tumours¹⁶ that sometimes may not be defined radiologically (Fig. 3).

Nail psoriasis is characterized by altered ventral nail plate ultrasound feedback¹⁷, which can help us differentiate it from onychomycosis and allows us to monitor treatment's response.¹⁸

Cosmetic dermatology

Dermatologists' interest for this diagnostic technique was renewed by its medical aesthetics applications.

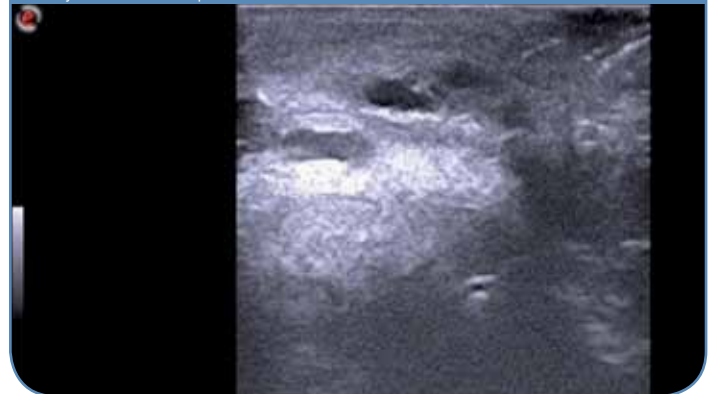
Cosmetic fillers display a set of sonographic patterns that allow us to detect and identify which type of filler was used¹⁹ and help us in the event of complications with these agents.²⁰

Skin aging assessment through sub-epidermal hypoechoic halo analysis²¹ is another useful ultrasound application since its thickness increases with photo-aging. Ultrasound is also used to assess skin's response to treatments such as laser²², mesotherapy²³ or photodynamic therapy²⁴ (Fig. 4).

How ultrasound works and which devices are suitable for skin ultrasound

Ultrasounds are sound waves with non-audible frequencies above 20,000 Hz generated by crystals which have the ability to emit these waves in response to an electrical stimulus and to convert the reflected echo of these ultrasounds into electrical signals, this is known as piezoelectric effect.

Figure 4 Upper lip implant. Its vascular appearance displays if it is made of hyaluronic acid or poliacrilamida



Piezoelectric crystals, which are located in transducers or probes, emit electrical signals to the processing unit. This unit converts electrical signals into greater or lesser intensity points of on a screen (B Mode image).

B Mode images represent a longitudinal or transverse line based on probe's orientation with respect to the structure being examined.

The greater the frequency of the ultrasound, the lower is its ability to penetrate the tissue and the greater is the ability to distinguish echoes from adjacent structures (resolution).

In dermatology, we are interested in surface structures and very high resolution to discriminate echoes. High frequency (above 7.5 MHz) wideband probes are therefore the most suitable transducers, since they supply us with the flexibility to study structures at different depths. Examination probes must be linear ones, as we are interested in structures which are parallel to the body's surface.

Esaote has provided worldwide high performance MSK ultrasound solutions for many years, pioneered ultrasound imaging availability up to 18 MHz high frequencies also on portable systems. The capability to enhance power Doppler frequency range up to 14,3 MHz also delivers incredible sensitivity for extremely low flows detection.

At EUROSON 2012, Esaote was also pleased to announce a new innovation in superficial ultrasound imaging, further increasing resolution with a new probe delivering an exceptional 15-22 MHz bandwidth.

Since ultrasound waves are greatly attenuated when transmitted through air, a gel or a stand-off must be placed between the skin and the transducer to facilitate transmission. Unlike conventional ultrasound, skin ultrasound assesses surface structures and is performed by slightly positioning the transducer on the gel placed over the skin, without applying pressure.

Conclusion

Skin ultrasound is a powerful, non-invasive, cost-effective and real-time technique that improves your daily practice when diagnosing, treating and monitoring skin tumours, vascular tumours, skin inflammatory diseases, nail lesions and cosmetic procedures.

Esaote S.p.A.

International Activities: Via di Caciolle 15 - 50127 Florence, Italy - Tel. +39 055 4229 1 - Fax +39 055 4229 208 - international.sales@esaote.com - www.esaote.com
Domestic Activities: Via A. Siffredi, 58 16153 Genoa, Italy, Tel. +39 010 6547 1, Fax +39 010 6547 275, info@esaote.com

References

1. Wortsman X, Jemec G. Common Inflammatory Diseases of the Skin: From the Skin to the Screen. *Advances in Psoriasis and Inflammatory Skin Diseases*. 2010;2:9–15.
2. Wortsman X, Jemec GBE. High Frequency Ultrasound for the Assessment of Hidradenitis Suppurativa. *Dermatol Surg*. 2007;33:1–3.
3. Wortsman X, Jemec GBE, Sazunic I. Anatomical detection of inflammatory changes associated to plantar warts. *Dermatology*. 2010;220:213–7.
4. Wortsman X, Sazunic I, Jemec GBE. Sonography of Plantar Warts. *J Ultrasound Med*. 2009;28:787–93.
5. Li SC, Liebling MS, Haines KA, Weiss JE, Prann A. Initial evaluation of an ultrasound measure for assessing the activity of skin lesions in juvenile localized scleroderma. *Arthritis Care Res*. 2011;63:735–42.
6. Gutierrez M, Filippucci E, Bertolazzi C, Grassi W. Sonographic monitoring of psoriatic plaque. *J Rheumatol*. 2009;36:850–1.
7. Filippucci E, Goteri G, Brandozzi G, Lemme G, Campanati A, Grassi W, et al. Clinical, power Doppler sonography and histological assessment of the psoriatic plaque: short-term monitoring in patients treated with etanercept. *Br J Dermatol*. 2011;164:33–7.
8. Kuwano Y, Ishizaki K, Watanabe R, Nanko H. Efficacy of diagnostic ultrasonography of lipomas, epidermal cysts, and ganglions. *Arch Dermatol*. 2009;145:761–4.
9. Wortsman X. Applications of High Resolution and High Frequency ultrasound in Vascular lesions of the skin. *Aplicaciones del Ultrasonido de Alta Resolución en Lesiones Vasculares de Piel*. *Revista Chilena de Dermatología*. 2008;24:227–32.
10. Bobadilla F, Wortsman X, Muñoz C, Segovia L, Espinoza M, Jemec GBE. Pre-surgical high resolution ultrasound of facial basal cell carcinoma: correlation with histology. *Cancer Imaging*. 2008;22:163–72.
11. Mogensen M, Nürnberg BM, Forman JL, Thomsen JB, Thrane L, Jemec GB. In vivo thickness measurement of basal cell carcinoma and actinic keratosis with optical coherence tomography and 20-MHz ultrasound. *Br J Dermatol*. 2009;160:1026–33.
12. Wortsman X, Wortsman J. Clinical usefulness of variable frequency ultrasound in localized lesions of the skin. *J Am Acad Dermatol*. 2010;62:247–56.
13. Chami L, Lassau N, Chebil M, Robert C. Imaging of melanoma: usefulness of ultrasonography before and after contrast injection for diagnosis and early evaluation of treatment. *Clin Cosmet Investig Dermatol*. 2011;4:1–6.
14. Vilana R, Puig S, Sanchez M, Squarcia M, Lopez A, Castel T, et al. Preoperative assessment of cutaneous melanoma thickness using 10-MHz sonography. *AJR Am J Roentgenol*. 2009;193:639–43.
15. Wortsman X, Calderon P, Baran R. Finger retronychia detected early by 3D ultrasound examination. *J Eur Acad Dermatol Venereol*. 2011 May 30. Epub ahead of print.
16. Wortsman X, Wortsman J, Soto R, Saavedra T, Honeyman J, Sazunic I, et al. Benign Tumors and Pseudotumors of the Nail: A Novel Application of Sonography. *J Ultrasound Med*. 2010;29:803–16.
17. Gutierrez M, Wortsman X, Filippucci E, De Angellis R, Filosam G, Grassi W. High Frequency Sonography in the Evaluation of Psoriasis: Nail and Skin Involvement. *J Ultrasound Med*. 2009;28:1569–74.
18. Wortsman X, Holm EA, Jemec GB, Gniadecka M, Wulf HC. Ultrasonido de alta resolución (15 MHz) en el estudio de la uña psoriática. *Rev Chilena Radiol*. 2004;10:6–11.
19. Wortsman X, Wortsman J, Orlandi C, Cardenas G, Sazunic I, Jemec GBE. Ultrasound detection and identification of cosmetic fillers in the skin. *J Eur Acad Dermatol Venereol*. 2011 mar 21. Epub ahead of print.
20. Schelke LW, Van Den Elzen HJ, Erkamp PP, Neumann HA. Use of ultrasound to provide overall information on facial fillers and surrounding tissue. *Dermatol Surg*. 2010;36 Suppl 3:1843–51.
21. Gniadecka M. Effects of age on dermal echogenicity. *Skin Res Technol*. 2001;7:204–7.
22. Tierney EP, Hanke CW, Petersen J, Bartley T, Eckert JR, McCutchen C. Clinical and echographic analysis of ablative fractionated carbon dioxide laser in the treatment of photodamaged facial skin. *Dermatol Surg*. 2010;36:2009–21.
23. Lacarrubba F, Tedeschi A, Nardone B, Micali G. Mesotherapy for skin rejuvenation: assessment of the subepidermal lowechogenic band by ultrasound evaluation with cross-sectional B-mode scanning. *Dermatol Ther*. 2008;21:S1–5.
29. Zane C, Capezzeri R, Sala R, Venturini M, Pinton CP. Clinical and echographic analysis of photodynamic therapy using metilaminolevulinat as sensitizer in the treatment of photodamaged facial skin. *Lasers Surg Med*. 2007;39:203–9.