

Developments in musculoskeletal ultrasound

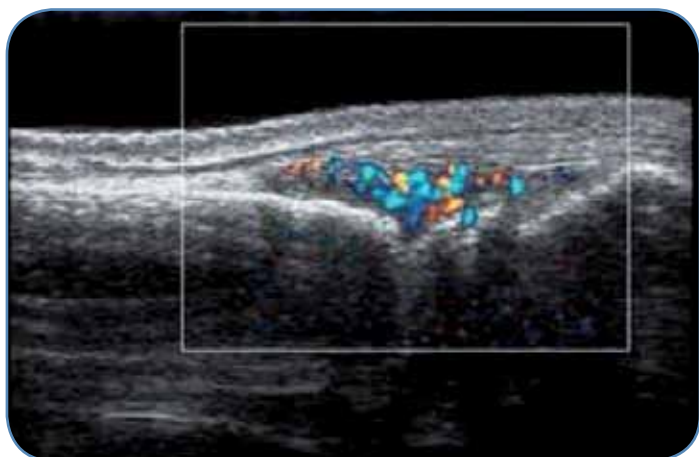
and clinical applications

“Ultrasound technology’s innovations supply extraordinary power for clinical development in the MSK Ultrasound imaging field thanks to their real-time performance, high tissue resolution, advanced features and reliable cost.”

Andrea S. Klauser, Associated Professor of Radiology, Medical University Innsbruck, Austria

The applications of US in the MSK field are expanding thanks to the impressive technology developments, offering the user advantages of real-time performance, superb tissue imaging and a wide choice of advanced new clinical investigations.

Over the past 10 years, huge improvement in image quality have been achieved by the industries developments such as broadband transducer technology (up to 18 MHz), harmonic and compound imaging, improved focusing, beam steering as well as Color Doppler imaging. Joint and tendon surface visibility has been greatly improved, as well as the assessment of structures with specular surface echoes such as tendons, nerves and muscles.



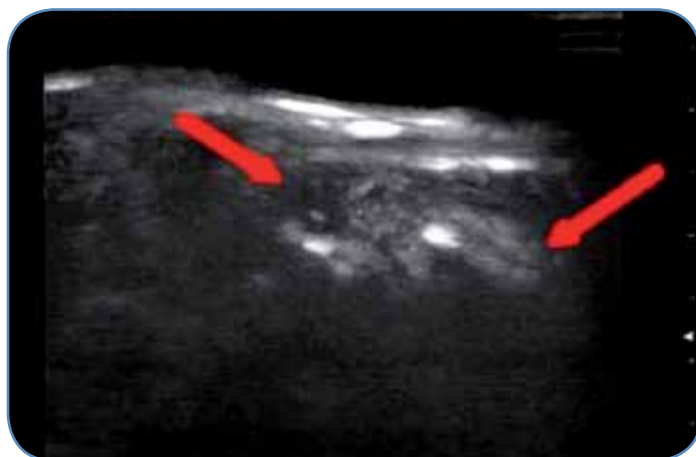
This technique can help to overcome anisotropy artefacts and to better differentiate insertional tendonitis, where often a part of the fibres run an oblique course causing hypoechoic patterns of uncertain pathological value.

A better sensitivity for the detection of low flow in small and superficial vessels is now available thanks to Power Doppler imaging improvements; the latter is of interest in rheumatologic conditions, tumour and overuse assessment.

PDUS/CDUS has been shown to be capable of detecting vascularity in synovial proliferations, in rheumatological inflammatory disease. Being able to be more sensitive than clinical assessment, the impact on therapy and follow up in treatment are better targeted when improved grading of disease activity is achievable.

PDUS in addition to gray-scale sonography has also been useful in the assessment of tendon neovascularization in patients with chronic achillodynia, because the presence of blood flow was associated with stronger pain, discomfort and physical restriction.

A new field of applications in MSK imaging is based on US contrast agents (CEUS) being capable to improve the detection of low-volume blood flow by increasing the signal-to-noise ratio. Microbubbles can prove vascularity in terms of activity or inactivity in synovial tissue, which is the target of new treatment regimens in rheumatologic diseases. This is of importance because vascularization of the hypertrophied synovium correlates with



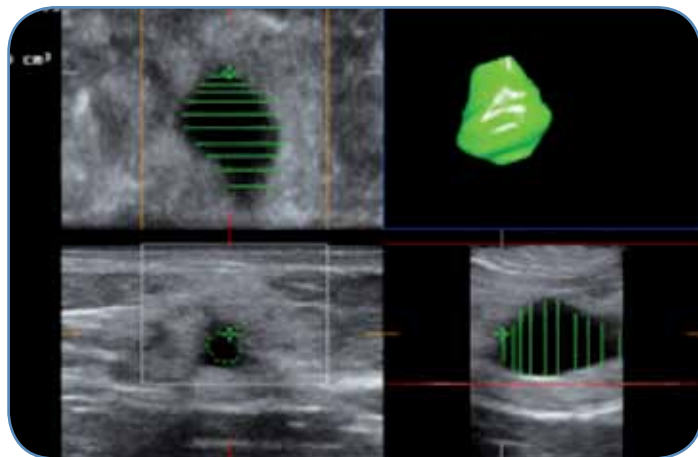
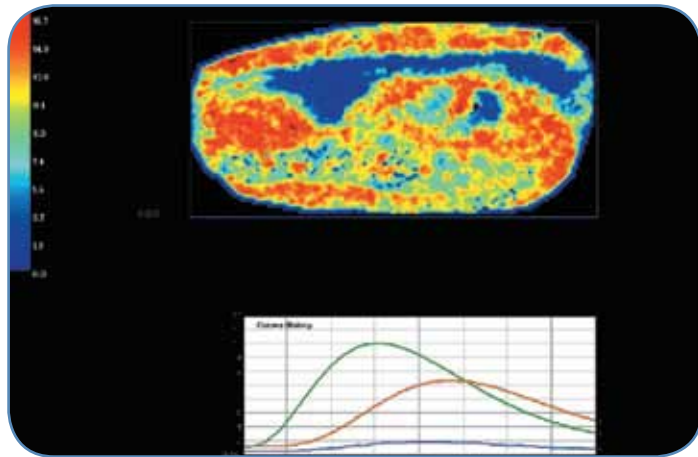
disease activity. The role of CEUS in routine diagnosis and follow-up of inflammatory rheumatic diseases is not yet established, but - by using US contrast agents - several studies have shown significantly improved detection of vascularity. At present, CEUS is of particular interest for clinical studies in monitoring new anti-inflammatory drugs used to treat rheumatological diseases.

The objective quantification of CEUS in the musculoskeletal system, since there are few publications available, is still under evaluation as intra- and inter-observer reliability has not yet been adequately proven.

Quantification of supraspinatus tendon enhancement was carried out using the determination of region of interest, dedicated quantification and software analysis. Anyway, to clarify whether computer-based quantification is superior to subjective vascular-

ity grading, quantification software tools need further evaluation in MSK US applications. The latter specially applied to therapeutic follow-up of rheumatological diseases.

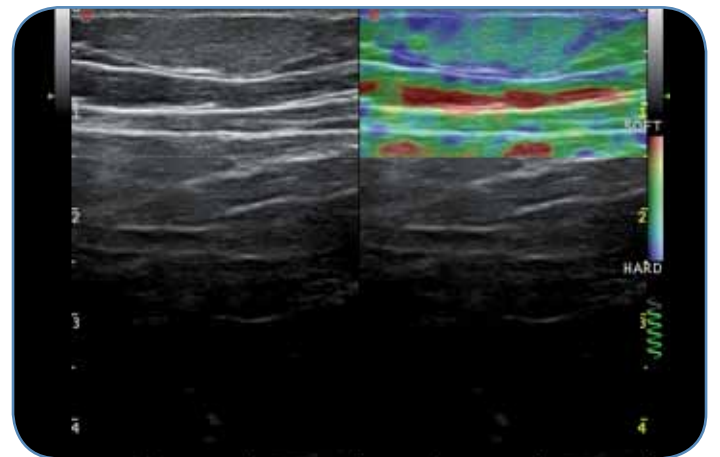
In case of measuring altered tissue vascularity and lesion extent (e.g. synovial proliferation, tumours) the use of threedimensional imaging (3-D imaging) could be helpful, because it can be carried out in B-Mode, Doppler Mode and in CEUS giving the opportunity to better understand the pathology and improved measurements after acquiring volumetric data. Two independent investigators have performed a 3D imaging of PDUS for quantification in the assessment of arthritis during anti-inflammatory



treatment, showing good to excellent interobserver reliability. Three-dimensional imaging is further useful in the assessment of muscle injuries and of synovitis in knees with osteoarthritis and has a further potential use (4D) in guiding tumor biopsies.

As pathological and surrounding healthy tissue often present with the same echogenicity, it is sometimes difficult or even impossible to distinguish the difference between them by means of conventional US. In breast, thyroid and prostate cancers and lymph node characterization, inflammation or tumours leading to changes in tissue elasticity have already been evaluated. Differentiation of tendon alterations in MSK imaging may be difficult since edema, haemorrhage, mucoid degeneration of partial tears present as isoechoic alterations.

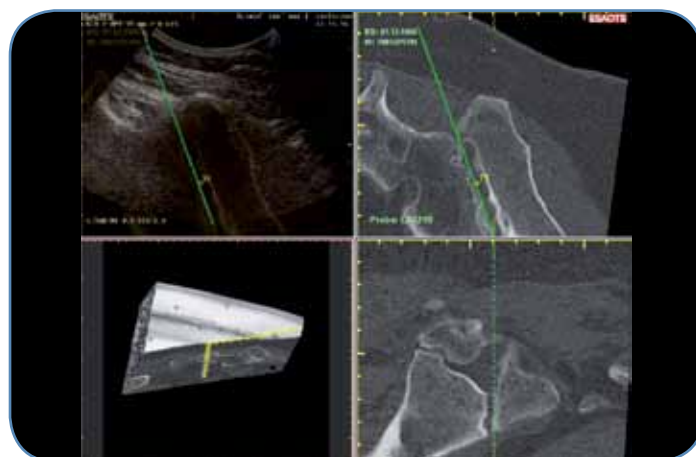
A new development called sonoelastography (EUS) can be used for assessing tissue elasticity under real-time conditions by measurement of tissue displacement. Sonoelastography (EUS) can be applied in MSK disorders as additional information to B-Mode imaging with interesting applications. Initial studies in estimation of elasticity for characterization of Achilles tendons in healthy volunteers and extensor tendon insertion in patients complaining of lateral epicondylitis, has shown promising results. In the detection of intratendinous and peritendinous alterations of lateral epicondylitis real-time EUS was valuable. It facilitated differentiation between healthy and symptomatic extensor tendon. When compared to healthy volunteers presenting with hard tendons structures, preliminary results revealed distinct softening of the



symptomatic Achilles tendons. EUS shows its clinical value where identical grey-scale values need a better differentiated representation of tissue softening. The same applies to the clearer delineation of the extent and degree of tendinosis. EUS helps here to detect tendon degeneration earlier and thus impacts decisions of therapeutic nature.

Ultrasound and MRI guidance can be used in MSK interventions for precise needle placements in peripheral joints and for instance sacroiliac joints. These modalities can replace fluoroscopy or CT guidance in cases where avoidance of radiation exposure is imperative. In selected cases the merge of information (Fusion Imaging) from cross-sectional imaging such as MRI or CT into US-guided real-time interventions could open up new horizons for US-guided interventions.

For MSK imaging Virtual real-time sonography seems promising to guide injections into the sacroiliac joint and for injection of facet joints. The needle insertion can be guided sonographically for intraarticular injection by using a navigator technology relying on bony extra- and intraarticular landmarks which are provided by the CT scan. For the future of US generally and this is true also for MSK US, dedicated teaching and training of young investigators and radiological junior staff is important. Evaluations were done to guide interventions by using a "needle tracker". This might be a valuable teaching tool in targeting oriented needle guidance. A magnetic device on top of a syringe provides real-time needle positioning and angulation information, as well as the alignment with internal markers placed in the targeted area. This improves the teaching of free hand interventions which involve real-time needle positioning and angulation.



*Andrea S. Klauser
Associated Professor of Radiology
Medical University Innsbruck
Austria*

Clinical Reference: Skeletal Radiol, DOI 10-1007/s00256-009-0782-y – Developments in musculoskeletal ultrasound and clinical applications – August 2009

Esaote S.p.A.

International Activities: Via di Caciolle 15 - 50127 Florence, Italy - Tel. +39 055 4229 1 - Fax +39 055 4229 208 - international.sales@esaote.com - www.esaote.com
Domestic Activities: Via A. Siffredi, 58 16153 Genoa, Italy, Tel. +39 010 6547 1, Fax +39 010 6547 275, info@esaote.com

*Products and technologies included in the document might be not yet released or not approved in all the countries.
The use of contrast agents in the USA is limited by FDA to left ventricle opacification and visualization of the left ventricular endocardial border.*