

Real-Time Elastosonography

Useful Tool for Refining the Presurgical Diagnosis
in Thyroid Nodules with Indeterminate or Nondiagnostic
Cytology and for Predicting Malignancy



Thyroid ultrasound (US) is useful for detecting and characterizing nodular disease which prevalence being dramatically increased in iodine-deficient areas. The great majority of nodules are benign, less than 5% of them being malignant¹⁻⁹. Fine-needle aspiration (FNA) is the best single test (invasive) for differentiating between malignant and benign lesions¹⁰⁻¹³, while US has the advantage of being a non-invasive procedure and of giving immediate information¹⁴⁻¹⁷. Several studies establish the usefulness of US in the diagnosis of benign and malignant nodules. Non-palpable nodules are detected by US in 13–50% of the general population^{4,36}, raising the question of which nodules warrant evaluation by FNA.

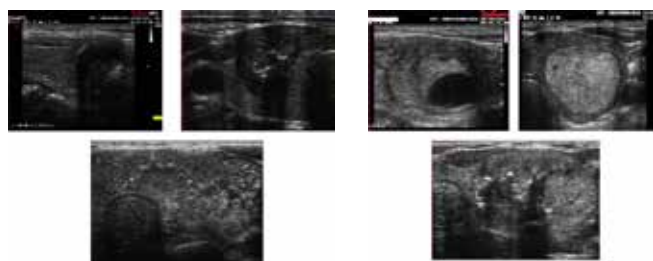
US Elastography is a dynamic technique based upon the principle that the softer tissues deform easier than the harder parts under compression by an external force. This elasticity can be assessed by measuring the degree of distortion of the US beam^{21,22}. Moreover, malignant lesions are often associated with changes in the mechanical properties of a tissue, and US Elastography can differentiate cancers from benign²³⁻²⁹.

Conventional US

The echographic patterns more frequently associated with thyroid carcinoma are hypoechogenicity of the nodule with respect to surrounding parenchyma, the absence of halo sign and the presence of microcalcifications (Figure 1)³⁸⁻⁴². However, it is widely recognized that any single echographic pattern cannot be considered specific for malignancy.

Figure 1 Ultrasound (US) patterns in thyroid nodules

Malignant nodule	Benign nodule
Hypoechogenic	Anechoic or hyperechoic
Absent halo sign	Uniform, thin halo
Irregular margins	Regular margins
Microcalcifications	Egg-shell calcifications



In a prospective study¹⁴, the combination absent halo sign/presence of microcalcifications and increased intranodular vascularization was strongly associated with malignancy. While the specificity of this combination was very high (97%), the sensitivity was very low (17%), being observed in only 5/30 carcinomas (Table 1).

Table 1 Echographic patterns and histology in 104 patients with thyroid nodule

US patterns	Carcinoma (n=30)	Benign (n=74)	P	Specificity (%)	Sensitivity (%)
Halo-/Microcal IBF	5	2	<0.01	97.2	16.6
Halo-/Hypoecho IBF	13	6	<0.0001	91.8	43.3
Hypoecho/Calcifications IBF	6	8	<0.20	89.1	20

US, ultrasound; Halo-, absent halo sign; Microcal, microcalcifications; Hypoecho, Hypoechogenicity; IBF intranodular blood flow. Modified from Rago et al (1998, *European Journal of Endocrinology* 138: 41-46) with permission.

The American Society of Radiologists in Ultrasound¹⁷ has reviewed US patterns associated with cancer in thyroid nodules (Table 2). In particular, US features associated with malignancy were microcalcifications, hypoechogenicity, irregular margins or absent halo sign, solid pattern, intranodular vascularization, and shape (taller than wide). All these patterns taken singly do not have sufficient predictive value. When multiple patterns suggestive of malignancy are simultaneously present in a nodule the specificity increases but the sensitivity becomes unacceptably low.

Table 2 Ultrasound signs suggestive of malignancy

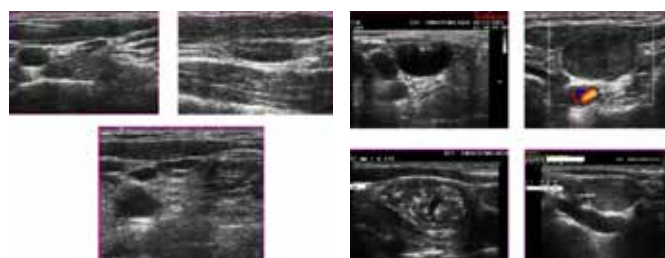
US patterns	Sensitivity (%)	Specificity (%)	PPV (%)	NPV (%)
Microcalcifications (14,15,38-40)	6.1-59.1	85.8-95.0	24.3-70.7	41.8-94.2
Hypoechogenicity	26.5-87.1	43.4-94.3	11.4-68.4	73.5-93.8
Irregular margins or no halo sign (40)	17.4-77.5	38.9-85.0	15.6-27.0	88.0-92.1
Solid (39-41)	26.5-87.1	43.4-94.3	11.4-68.4	73-93.8
Intranodular vascularity (14,15,39-41)	54.3-74.2	78.6-80.8	24.0-41.9	85.7-97.4
Taller than wide (39)	92.5	92.5	66.7	74.8

PPV, positive predictive value; NPV, negative predictive value

However, in a recent consensus on the diagnosis of thyroid nodular disease it has been agreed that US is essential to select the nodules that warrant FNA¹⁷⁻²⁰. If nodules are present, US examination should be extended to the neck lymph nodes. Metastatic lymph nodes appear as rounded, solid with absence of the hyperechoic striae corresponding to the hilus, or cystic. Sometimes the pattern is solid and inhomogeneous, with spot calcifications (Figure 2).

Figure 2 Ultrasound (US) patterns in lymph nodes

Inflammatory (typical) lymph node	Suspicious (atypical) lymph node
Solid	Solid, mixed/cystic
Hypoechogenic	
Ellipsoid shape	Round shape
Central hyperechoic line (ilus)	Central hyperechoic line (ilus): absent



Practice points

- In thyroid nodules, US features suggestive of malignancy are microcalcifications, hypoechogenicity, irregular margins or absent halo sign, solid aspect, intranodular vascularization and shape (taller than wide);
- these patterns taken singly are poorly predictive;
- when multiple patterns suggestive of malignancy are simultaneously present the specificity of US increases, the sensitivity decreases;
- neck lymph nodes: metastatic lymph nodes appear rounded, solid with absence of the hyperechoic striae corresponding to the hilus, or cystic.

US Elastography

Tissue elasticity was initially measured by an off-line processing of US images obtained before and after compression by the probe, but this technique is cumbersome and time-consuming⁴⁴. More recently, methods assessing real-time measurement of tissue strain were developed: i.e. *spatial correlation method*, *phase-shift tracking method*, and *combined autocorrelation method (CAM)*. Each method appears to have advantages and disadvantages (Table 3).

Table 3 Advantages and disadvantages of ultrasound elastography (USE)

Method	Advantages	Disadvantages	Precision
Spatial correlation	Displacement two dimensions: longitudinal, lateral	Lengthy	Moderate
Phase-shift tracking	Precise longitudinal tissue motion	Fails to measure	High
Combined autocorrelation CAM	Rapid and accurate detection of longitudinal displacement	None	High
Off-line processed	Quantitative measure of stiffness	Labour-intensive and time-consuming	






The *spatial correlation method* is used to demonstrate displacement in two dimensions (longitudinal and lateral), but the processing speed is very slow, which is a disadvantage for realtime assessment.

The *phase-shift tracking method* is based on an autocorrelation method that is well known as a principle of colour Doppler ultrasonography. It precisely determines longitudinal tissue motion, but poorly compensates for movements in the lateral direction, which is a disadvantage for free-hand compression. The more recently developed CAM can compensate for up to about 4 mm of lateral slip^{45,46}.

The *CAM method* is based on US elastographic where the probe is placed on the neck, a light pressure is exerted, and a box which includes the nodule to be evaluated is selected by the operator. The principle of US elastography is to acquire two ultrasonographic images (before and after tissue compression by the probe), and to track tissue displacement by assessing the propagation of the beam. The CAM dedicated software is able to

provide an accurate measurement of tissue distortion. The US elastogram is displayed over the B-mode image with a superimposed colour scale to differentiate harder & softer component. The US elastographic image is matched with an elasticity colour scale and classified by using the elasticity score of Ueno and co-workers (Figure 3)⁴⁷.

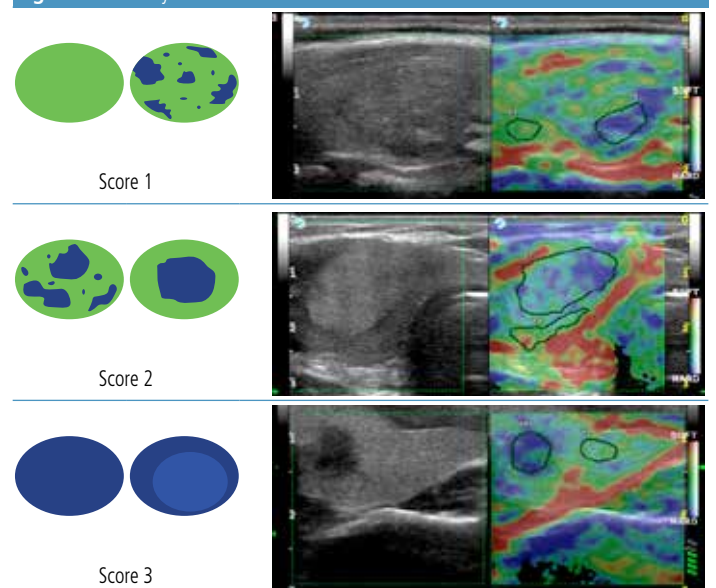
Figure 3 Colour scale of Ueno and co-workers

Score	Description
 1	Elasticity in the whole nodule
 2	Elasticity in a large part of the nodule
 3	Elasticity only at the peripheral part of the nodule
 4	No elasticity in the nodule
 5	No elasticity in the nodule and in the posterior shadowing

To simplify thyroid nodular classification, the score developed by Ueno and Ito³⁴ for the breast was modified as follows by Rago at all:

- **score 1** included scores 1 and 2 of the previous classification and defined nodules with high elasticity;
- **score 2** was maintained as an intermediate score;
- **score 3** included scores 4 and 5 of the previous classification and defined nodules with low elasticity (Figure 4).

Figure 4 Elasticity Score



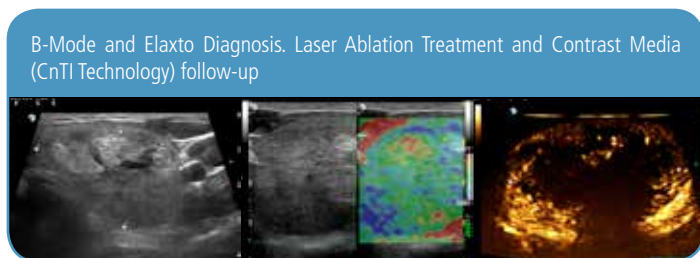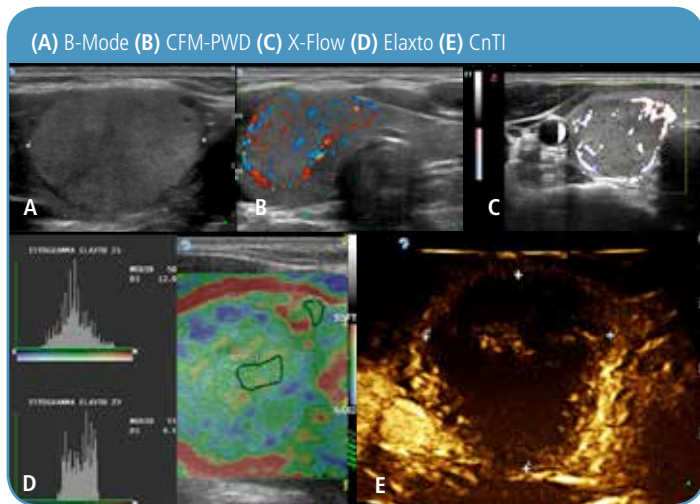
Conclusion

Ultrasound Elastography (USE) is a powerful new diagnostic tool that assesses hardness as an indicator of malignancy in thyroid nodules. USE has a high specificity and sensitivity independent of the nodule size, this predictive value being maintained in follicular lesions.

Available data suggest that USE is the best available non-invasive tool comparable to FNA for the evaluation of thyroid nodules, provided that the nodule is solid and devoid of coarse calcifications. Thus conventional US retains importance for selection of nodules in which USE is predictive. Ultrasound Elastography has great potential as a new tool for the diagnosis of thyroid cancer, especially in nodules with indeterminate cytology.

Furthermore the combination of both Technologies, Elaxto and CnTI Contrast Media Modality, allows the best assessment in thyroid nodules evaluation.

Technology



Esaote S.p.A.

International Activities: Via di Caciolle 15 - 50127 Florence, Italy - Tel. +39 055 4229 1 - Fax +39 055 4229 208 - international.sales@esaote.com - www.esaote.com
Domestic Activities: Via A. Siffredi, 58 16153 Genoa, Italy, Tel. +39 010 6547 1, Fax +39 010 6547 275, info@esaote.com

References

1. Tunbridge WMG, Evered DC, Hall R et al. The spectrum of thyroid disease in a community: The Whickham Survey. *Clinical Endocrinology* 1977; 7: 481-493.
2. Mazzaferri EM. Management of a solitary thyroid nodule. *The New England Journal of Medicine* 1993; 328: 553-559.
3. Ezzat S, Sarti DA, Cain DR et al. Thyroid incidentalomas. Prevalence by palpation and ultrasonography. *Archives of Internal Medicine* 1994; 154: 1838-1840.
4. Tan GH & Gharib H. Thyroid incidentalomas: management approaches to non palpable nodules discovered incidentally on thyroid imaging. *Annals of Internal Medicine* 1997; 126: 226-231.
5. Rago T, Chiovato L, Aghini-Lombardi F et al. Non-palpable thyroid nodules in a borderline iodine-sufficient area: detection by ultrasonography and follow-up. *Journal of Endocrinology Investigation* 2001; 24: 770-776.
6. Vander JB, Gaston EA & Dawber TR. The significance of nontoxic thyroid nodules. *Annals of Internal Medicine* 1968; 69: 537-540.
7. Aghini-Lombardi F, Antonangeli L, Martino E et al. The spectrum of thyroid disorders in an iodinedeficient community: the Pescopagano survey. *The Journal of Clinical Endocrinology and Metabolism* 1999; 84: 561-566.
8. Thyroid carcinoma. National Comprehensive Cancer Network U.S. Preventive services task force ratings: strength of recommendations and quality of evidence. *Guide to clinical preventive services, 3rd edn., Periodic Update, 2000-2003 Agency for healthcare research and quality, Rockville, MD.9. 2004 CA: A Cancer Journal for Clinicians.*
9. Jemal A, Murray T, Ward E et al. Cancer statistics 2005. *CA: A Cancer Journal for Clinicians* 2005; 55: 10-30.
10. Gharib H. Fine-needle aspiration biopsy of the thyroid nodules: advantages, limitations and effect. *Mayo Clinic Procedure* 1994; 69:44-49.
11. Suen KC. Fine-needle aspiration biopsy of the thyroid. *Canadian Medicine Association Journal* 2002; 167: 491-495.
12. Goellner JR, Gharib H, Grant CS et al. Fine needle aspiration cytology of the thyroid 1980 to 1986. *Acta Q5 Cytologica* 1986; 31:587-590.
13. Castro MR & Gharib H. Thyroid fine-needle aspiration biopsy: progress, practice, and pitfalls. *Endocrine Practice* 2003; 9: 128-136.
14. Rago T, Vitti P, Chiovato L et al. Role of conventional ultrasonography and color flow-doppler sonography in predicting malignancy in 'cold' thyroid nodules. *European Journal of Endocrinology* 1998; 138: 41-46.
15. Papini E, Guglielmi R, Bianchini A et al. Risk of malignancy in nonpalpable thyroid nodules: predictive value of ultrasound and color-Doppler features. *Journal Clinical Endocrinology and Metabolism* 2002; 87: 1941-1946.
16. Mandel SJ. Diagnostic use of ultrasonography in patients with nodular thyroid disease. *Endocrine Practice* 2004; 10: 246-252.
17. Frates MC, Benson CB, Charboneau JW, et al, Society of Radiologists in Ultrasound. Management of thyroid nodules detected at US: Society of Radiologists in Ultrasound consensus conference statement. *Radiology* 2005; 237: 794-800.
18. Cooper DS, Doherty GM, Haugen BR, et al, American Thyroid Association Guidelines Taskforce. Management guidelines for patients with thyroid nodules and differentiated thyroid cancer. *Thyroid* 2006; 2: 2-33.
19. Pacini F, Schlumberger M, Dralle H, et al, the European Thyroid Cancer Taskforce. European consensus for the management of patients with differentiated thyroid carcinoma of the follicular epithelium. *European Journal of Endocrinology* 2006; 154: 787-803.
20. AACE/AME Task Force on Thyroid Nodules. American Association of Clinical Endocrinologists and Associazione Medici Endocrinologi medical guidelines for clinical practice for the diagnosis and management of thyroid nodules. *Endocrine Practice* 2006; vol. 12: 63-102.
21. Lerner RM, Huang SR & Parker KJ. Sonoelasticity images derived from ultrasound signals in mechanically vibrated tissues. *Ultrasound in Medicine & Biology* 1990; 16: 231-239.
22. Ophir J, Alam SK, Garra B et al. Elastography: ultrasonic estimation and imaging of the elastic properties of tissues. *Proceedings of the Institution of Mechanical Engineers* 1999; 213: 203-233.
23. Garra BS, Cespedes EI, Ophir J et al. Elastography of breast lesions: initial clinical results. *Radiology* 1997; 202: 79-86.
24. Cochlin DL, Ganatra RH & Griffiths DF. Elastography in the detection of prostatic cancer. *Clinical Radiology* 2002; 57: 1014-1020.
25. Thomas A, Fischer T, Frey H et al. Real-time Elastography an advanced method of ultrasound: first results in 108 patients with breast lesions. *Ultrasound in Obstetrics and Gynecology* 2006; 28: 335-340.
26. Miyayaga N, Akaza H, Yamakawa M, Oikawa T et al. Tissue elasticity imaging for diagnosis of prostate: a preliminary report. *International Journal of Urology* 2006; 13: 1514-1518.
27. Yamakawa M, Nitta N, Shiina T et al. High-speed freehand tissue elasticity imaging for breast diagnosis. *Q6 Japanese Journal of Applied Physics* 2003; 42: 3265-3270.
28. Lyschchik A, Higashi T, Asato R et al. Cervical lymph node metastases: diagnosis at sonoelastography. *Radiology* 2007; 237: 202-211.
29. Giovannini M, Hooke LC, Bories E et al. Endoscopic ultrasound elastography the first step towards virtual biopsy? Preliminary results in 49 patients. *Endoscopy* 2006; 38: 1-5.
30. Ueno E, Ito A 2004 Diagnosis of breast cancer by elasticity imaging. *Eizo Joho Medical* 36:2-6
31. Ross DS. Editorial: Nonpalpable thyroid nodules-managing an epidemic. *The Journal of Clinical Endocrinology and Metabolism* 2002; 87: 1938-1940.
32. Braga M, Graf H, Ogata A et al. Aggressive behavior of papillary microcarcinoma in patient with Graves' disease initially presenting as cystic neck mass. *Journal of Endocrinological Investigation* 2002; 25: 250-253.
33. Khoo ML, Asa SL, Witterick IJ et al. Thyroid calcification and its association with thyroid carcinoma. *Head & Neck* 2002; 24: 651-655.
34. Kim EK, Park CS, Chung WY et al. New sonographic criteria for recommending fine-needle aspiration biopsy of non palpable solid nodules of the thyroid. *AJR. American Journal of Roentgenology* 2002; 178: 687-691.
35. Peccin S, de Castro JA, Furlanetto TW et al. Ultrasonography: is it useful in the diagnosis of cancer in thyroid nodules? *Journal of Endocrinological Investigation* 2002; 25: 39-43.
36. Frates MC, Benson CB, Doubilet PM et al. Can color Doppler sonography aid in the prediction of malignancy of thyroid nodules? *Journal of Ultrasound in Medicine* 2003; 22: 127-131.
37. Rago, G. Di Coscio, F. Basološ, M. Scutari, R. Elisei, P. Bertì, P. Miccoliti, R. Romani, P. Faviana, A. Pinchera and P. Vitti. Combined clinical, thyroid ultrasound and cytological features help to predict thyroid malignancy in follicular and Hurthle cell thyroid lesions: results from a series of 505 consecutive patients. *Clinical Endocrinology* (2007) 66, 13-20
38. Lyschchik A, Higashi T, Asato R et al. Thyroid gland tumor diagnosis at US elastography. *Radiology* 2005; 237: 202-211.
39. Shiina T, Nitta N, Ueno E et al. Real time tissue elasticity imaging using the combined autocorrelation method. *Journal of Medical Ultrasonics* 2002; 29: 119-128.
40. Yamakawa M & Shiina T. Strain estimation using the extended combined autocorrelation method. *Japanese Journal of Applied Physics* 2001; 40: 3872-3876.
41. Ueno E & Ito A. Diagnosis of breast cancer by elasticity imaging. *Eizo Joho Medical* 2004; 36: 2-6.