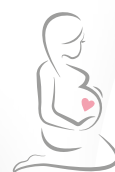

# BreastNav™ MRI

## a new horizon for Breast Imaging

Courtesy of  
Prof. Massimo Calabrese, Dr. Camilla Fachinetti,  
Dr. Alessandro Garlaschi and Dr. Giuseppe Rescinito



*Her Health*  
*Our Commitment*



**Augmented Insight™**

“BreastNav™ MRI is definitely highly advantageous and represents a major implementation in our second-look protocols, for its quick and easy management of breast fusion imaging.”



Dr. Alessandro Garlaschi, Dr. Giuseppe Rescinito & Prof. Massimo Calabrese  
Breast Diagnostic Department, San Martino Polyclinic Hospital, Genoa, Italy

## Introduction: Augmented Insight™, an Esaote smart solution applied to breast ultrasound imaging

Augmented Insight™ embeds all the solutions powered by Artificial Intelligence, developed by the Research & Development department at Esaote according to a multidisciplinary approach, across different modalities such as Ultrasound, MRI and Ebit.

Based on data-driven machine learning, Augmented Insight™ is designed to simplify the workflow in repetitive gestures, complex procedures, measurements or lesions analysis.

Esaote has developed the BreastNav™ MRI Augmented Insight™ solution specifically for breast US imaging.

## Background: a multimodality approach for breast cancer screening

Innovation is fundamental in radiology, where research and development of new technologies keep opening new possibilities in diagnostic and therapeutic fields.

In particular, for breast cancer care, a multidisciplinary approach is becoming increasingly important, leading to actual Breast Units, in which the patient is followed up along a complete pathway, starting from the diagnosis, to the lesion's follow-up, response to therapy prediction, and therapeutic procedure as an alternative to surgery.

The role of the breast radiologist is closely correlated to other important specialists, like surgeons, pathologists, oncologists, radiologists, and specialist nurses.

Breast cancer is the most common oncological disease for women worldwide. Increasingly, beside mammography-based screenings, a multimodality imaging approach is being used in the detection and monitoring of early stage cancer disease, with the aim of initiating appropriate treatment in order to decrease mortality.

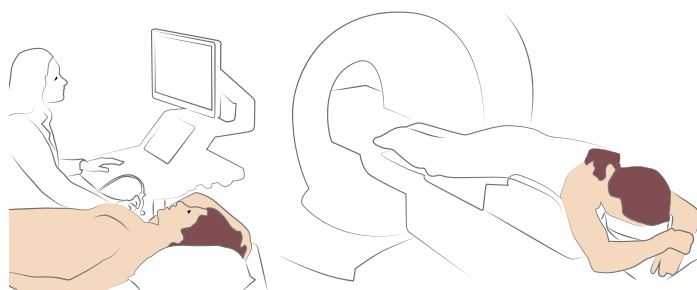
Several studies have been conducted to optimize breast MRI results that are to date very sensitive but still showing low to moderate specificity and moderate Positive Predictive Values (PVVs) for lesion characterization. In addition, technology evolution over recent years has made breast ultrasound an essential component of the diagnostic scenario.

In current practice, when a breast lesion is identified at MRI, a second look with targeted US is generally performed because it provides additional information to further characterize the target lesion and makes it possible to perform US-guided biopsies, which are less expensive and more comfortable for patients compared with MRI-guided ones.

Nevertheless, there is not always a correspondence between MR findings and targeted US due to several factors, including operator experience and position of patients. Furthermore, breast tissues are soft and easily deformable, the organ is

movable and breast size varies substantially among women; in addition, Breast MRI is routinely performed with patients in prone position, while US is performed with the patient in supine position.

As a result of varying the position of patients during clinical examinations, breast location, size and localization of potential internal lesions typically undergo significant variations, with substantial spatial displacement and misalignment. In some cases, these limitations do not allow the diagnosis to be concluded on a second look, and in such circumstances an MRI-guided biopsy could be necessary.



Traditional fusion imaging algorithms are not able to manage such important deformations, and several studies have been performed, requiring additional supine MRI sequences for the navigation with the US examination.

Nevertheless there are considerable disadvantages: first of all, supine MRI image quality is lower compared with prone MRI due to respiratory or heartbeat artefacts and to the use of non-dedicated coils; secondly, an additional MRI examination in the supine position is time-consuming, requires additional administration of contrast agent, or may be unavailable. For this reason, a new algorithm, based on 3D adaptive modelling Artificial Intelligence technology, has been developed, BreastNav™ MRI, to overcome such difficulties and to provide the fusion imaging between prone MRI and supine US, thus benefiting from multimodal approach for lesion detection and characterization.

## Technology: the role of BreastNav™ MRI in breast lesion detection and characterization

BreastNav™ MRI enables us to correlate prone MRI to supine US and to localize on the real time US, with patient supine, the spatial position of a reference anatomical target, related to a lesion under investigation, previously identified on prone-position MRI.

The hardware is based on an electromagnetic tracking system, with a transmitter and a receiver antenna mounted on a reusable bracket positioned on the linear probe (Fig. 1a).

“BreastNav™ MRI has guided me many times in finding a lesion I had previously identified in MRI more easily.”



Dr. Camilla Fachinetti – Director of Breast Diagnostic Imaging Unit, Valduce Hospital (Como, IT)

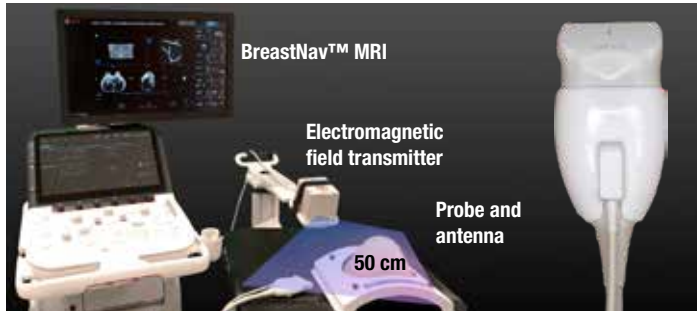


Fig. 1a: BreastNav™ MRI fusion imaging hardware components

The algorithm requires minimal user input and interaction and performs automatically a mathematical transformation of the MRI target spatial coordinates from prone to supine patient position, thanks to breast 3D shape modeling (Fig. 1b).

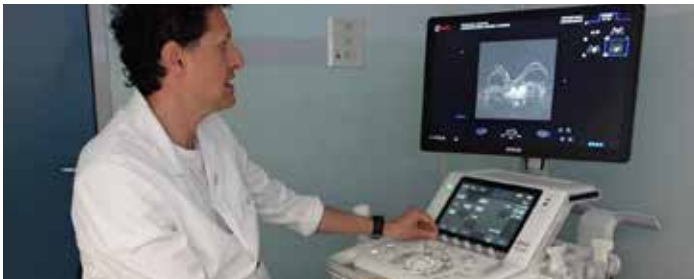

Fig. 1b: BreastNav™ MRI fusion imaging between US and MRI, in real-time investigation

The registration procedure between the two modalities prone MRI and supine US imaging is based on a 3D adjustable breast model. The first phase, powered by A.I., consists of an automatic breast (pink) and chest (blue) anatomy detection and segmentation of the MRI examination, uploaded via DICOM via USB/CD or PACS, and in the proposed positioning of five anatomical reference points. These points will be registered and translated into breast model coordinates: P1 nipple, P2-P3 median and lateral margins, P4 inframammary fold, P5 parasternal line (Fig. 2).

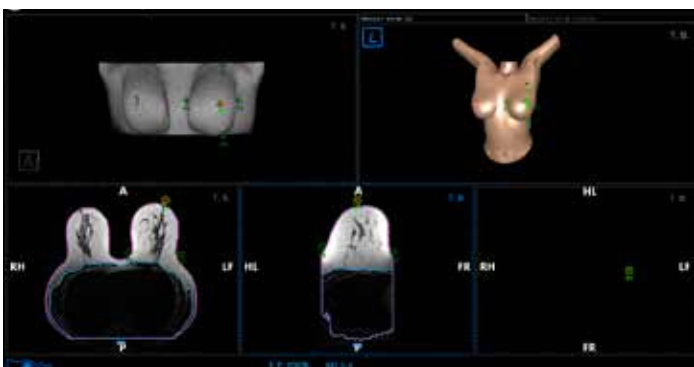


Fig. 2: Registration between 5 anatomical superficial points on prone MRI (left) and the 3D model (right);

In a second step user perform 2 acquisition sweeps to trace the profile of the reference patient’s breast, without any pressure, one horizontal from P2 to P3 and one vertical from P4 to P5 (Fig. 3).

This information, together with the points previously acquired will allow the algorithm to correlate prone MRI with supine US.

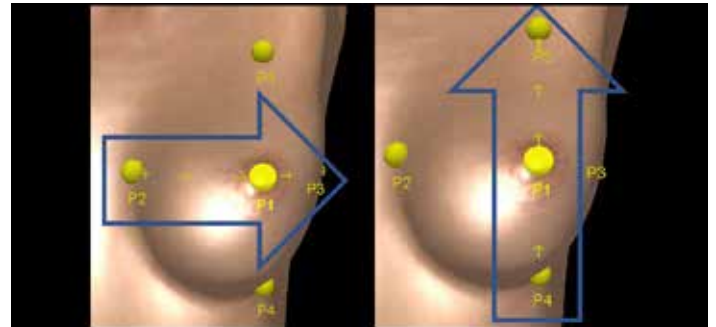


Fig. 3: Direction of horizontal (left) and vertical (right) sweeps registration procedure, performed with US probe directly on patient’s breast without any pressure

## Clinical benefits and drawbacks

The analysis focused on lesions identified in MRI, which require a second-look US examination. The collected sample is wide-ranging in terms of both the location of the injury –external and internal quadrants; superior, inferior and retroareolar – and the breast composition: dense, fatty or mixed, in sizes from very small to very large and even with some cases of prosthesis. BreastNav™ MRI Fusion Imaging technology, supported by A.I., can precisely co-record a breast lesion MRI performed in the prone position and its US correspondence in supine decubitus. The targets, previously marked in MRI, are located during US with a minimal mismatch (less than 1 cm) between the target and the suspected lesion, making it possible to perform the US-guided biopsy (Fig. 4-5), directly and as required. Moreover, the automatic MRI segmentation algorithm has yielded promising results, with fairly precise detection of the five landmarks required, thus considerably accelerating the entire BreastNav™ MRI workflow.

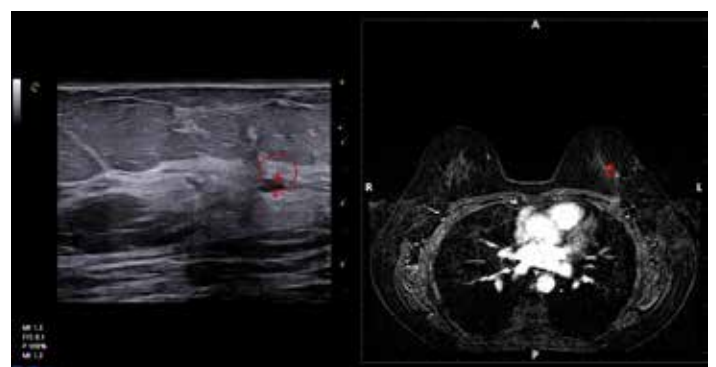


Fig. 4: MRI-US Navigation phase: minimum disalignment between the target and the lesion (QSE SX) in a fatty small breast

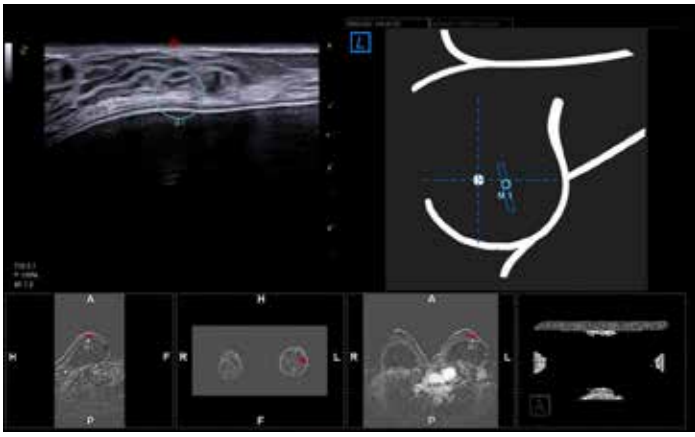


Fig. 5: MRI-US Navigation phase: perfect match between the retroareolar lesion and the target in a dense breast with prosthesis

BreastNav™ MRI technology enables us to save all data in the US archive for post-processing analysis and review, to print pictures of the target reference and US probe spatial position with fusion imaging and to print reports, also including BI-RADS® categorization (Breast Imaging Reporting and Data System-ATLAS of the American College of Radiology). During BreastNav™ MRI-US Fusion Imaging investigation other breast relevant US technologies such as microvessel imaging, elastography (Strain and/or Shear Wave technology) can be used or support the clinician in the lesion characterization (Fig. 6-7). Although the patient sample has grown considerably from the preliminary study and the algorithm performance has provided very good results, breast size, its tissue composition and the lesion's position can still affect the final accuracy.

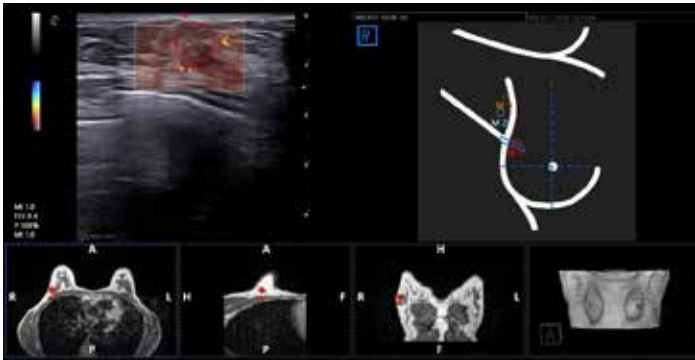


Fig. 6: microV technology for the detection of very small flows, associated with BreastNav™MRI

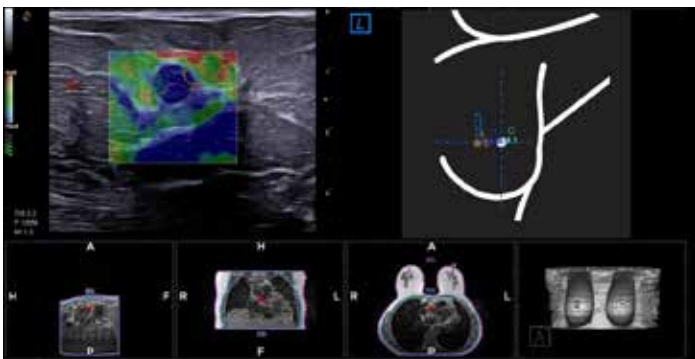


Fig. 7: US Strain Elastography evaluation (ElaXto, Esaote) associated with BreastNav™ MRI technology

This is because the deformation and the mammary gland slippage are not homogeneous among different patients and the variability observed among women is necessarily huge. For this reason, improvement in the machine learning procedure is needed, by increasing the big data cases in order to provide even more diagnostic confidence in the future.

## Conclusions

Integrated breast multimodal fusion imaging becomes possible, thanks to technology evolution. BreastNav™ MRI aims to manage the deformation induced by different patient positions, and to speed up the detection and characterization of lesions, visible on MRI and on real-time US, thus providing additional information to support the diagnosis, the follow-up of breast lesions and the response to the therapy prediction. Furthermore, this technology represents a valid alternative to the more complex, expensive and invasive option of VABB MRI-guided biopsy.

## References

- D'Onofrio S et al. *Valutazione preliminare di un algoritmo di Intelligenza Artificiale basato su modellizzazione del seno e fusione di immagini RM-US*, Poster No.: PS-17/68, Congress: SIRM 2020
- De Beni S et al. *Preliminary assessment of an Artificial Intelligence algorithm based on MRI breast modelling with US fusion*, Poster No.: C-07119, Congress: ECR 2020
- Kesson EM, Allardice GM, George WD, Burns HJG, Morrison DS *Effects of multidisciplinary team working on breast cancer survival: retrospective, comparative, interventional cohort study of 13722 women* BMJ 2012; 344 :e2718 doi:10.1136/bmj.e2718
- Aribal et al. *MRI-detected breast lesions: clinical implications and evaluation based on MRI/ultrasonography fusion technology* Japanese Journal Radiology 2020, 38: 94-5,
- Nakashima K et al. *MRI-detected breast lesions: clinical implications and evaluation based on MRI/ultrasonography fusion technology* Japanese Journal Radiology 2019, 37: 685-693
- Bernardi et al. *Effect of implementing digital breast tomosynthesis (DBT) instead of mammography on population screening outcomes including interval cancer rates: Results of the Trento DBT pilot evaluation* The Breast 50 (2020), 135-40, DOI: <https://doi.org/10.1016/j.breast.2019.09.012>
- Vourtsis A, Berg WA *Breast density implications and supplemental screening*. Eur Radiol. 2019;29(4):1762-1777. doi:10.1007/s00330-018-5668-8
- Di Grezia et al. *State-of-the-Art in Integrated Breast Imaging* Biomed Res Int. 2019; 2019:7596059, doi:1155/2019/7596059
- Mann RM et al. *Breast MRI: State of the Art* Radiology 2019; 292: 520-36, <https://doi.org/10.1148/radiol.2019182947>
- Abate A. et al. *Tecnica Di Fusione Delle Immagini Risonanza Magnetica-Ecografia "Real Time" Per La Caratterizzazione Delle Lesioni Mammarie* Poster AIS P13.1-2019
- Mazzei MA et al. *Efficacy of Second-Look Ultrasound with MR Coregistration for Evaluating Additional Enhancing Lesions of the Breast: Review of the Literature* Biomed Res Int. 2018; 2018:3896946, <https://doi.org/1155/2018/3896946>
- Aribal E et al. *Volume navigation technique for Ultrasound-guided biopsy of breast lesions detected only at MRI* AJR 2017,208:6,1400-1409
- Early Detection and Screening for Breast Cancer, Cathy Coleman, Elsevier, 2017, Rachel F. et al. *Screening Breast Ultrasound: Past, Present, and Future* American Journal of Roentgenology 2015 204:2, 234-240
- John McCarthy's definition of AI as the science and engineering of making intelligent machines, especially intelligent computer programs: <http://jmc.stanford.edu/articles/whatsai/whatsai.pdf>

Esaote S.p.A. sole-shareholder company  
Via Enrico Meloni 77, 16152 Genoa, ITALY, Tel. +39 010 6547 1, Fax +39 010 6547 275, [info@esaote.com](mailto:info@esaote.com)

BreastNav™ is powered by MedCom GmbH. BI-RADS® incorporates the Breast Imaging Reporting and Data System ATLAS of the American College of Radiology, Copyright 1992, 1993, 1995, 1998, 2003, and 2013. The developer of this product is independently owned and operated, and is not an affiliate of the American College of Radiology. The American College of Radiology is not responsible for the contents or operation of this product or its associated software, and expressly disclaims any and all warranties and liabilities, expressed or implied, in connection therewith. Technology and features are system/configuration dependent. Specifications subject to change without notice. Information might refer to products or modalities not yet approved in all countries. Product images are for illustrative purposes only. For further details, please contact your Esaote sales representative.