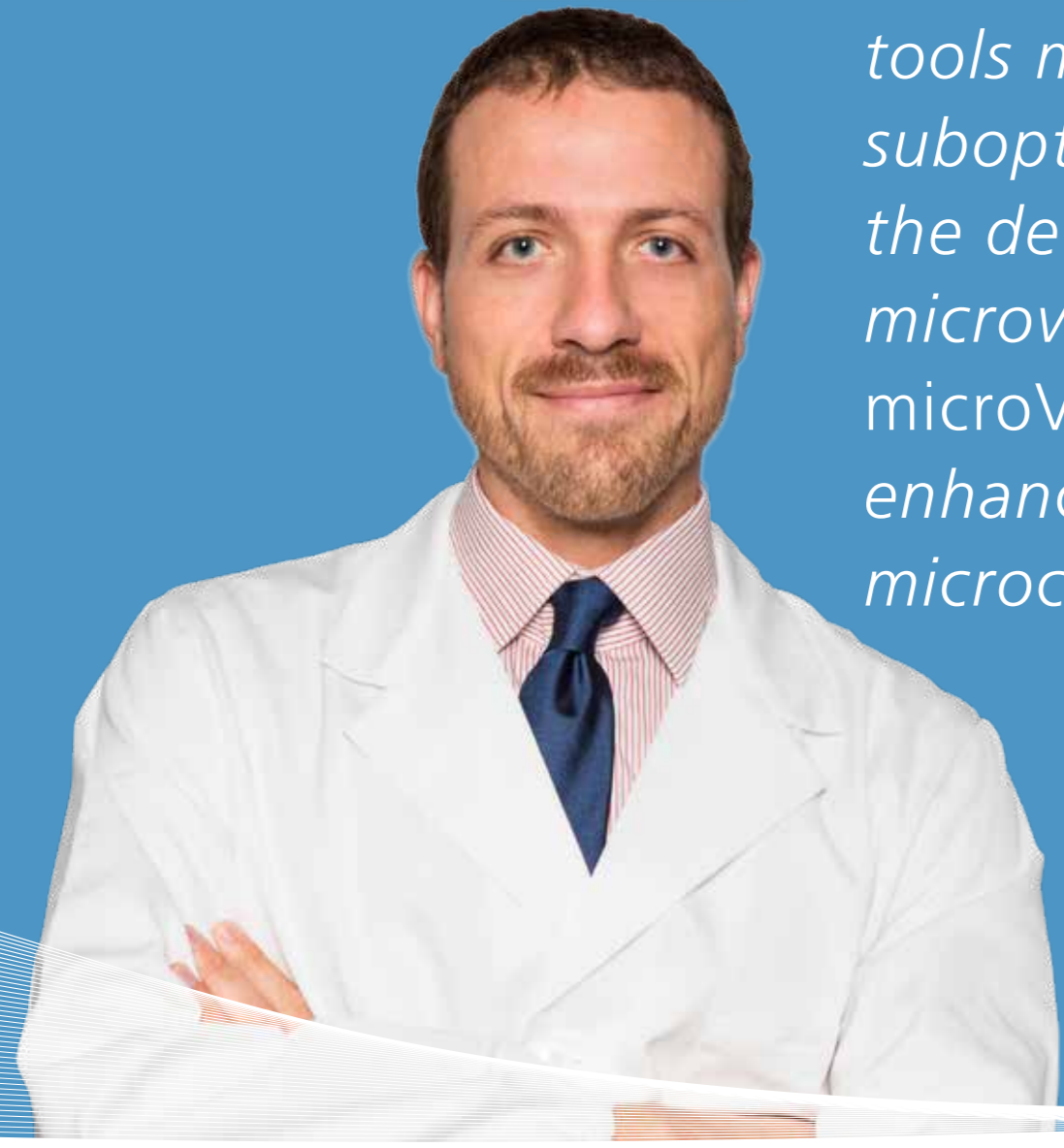



“ Conventional Color and Power Doppler tools may be suboptimal in the detection of microvasculature. *microV* may help enhance the visibility of microcirculation. ”

microV

microV in MSK Ultrasound examination

Case studies courtesy of

Prof. Luca Maria Sconfienza

Chair of Radiology Unit, IRCCS Istituto Ortopedico Galeazzi, Milan, Italy;
Professor of Radiology, University of Milan, Italy.

For the musculoskeletal system, visualization of the tissue Doppler signal is of paramount importance, as it allows inflammatory or angiofibroblastic activity within tendons, ligaments, and synovium to be detected.

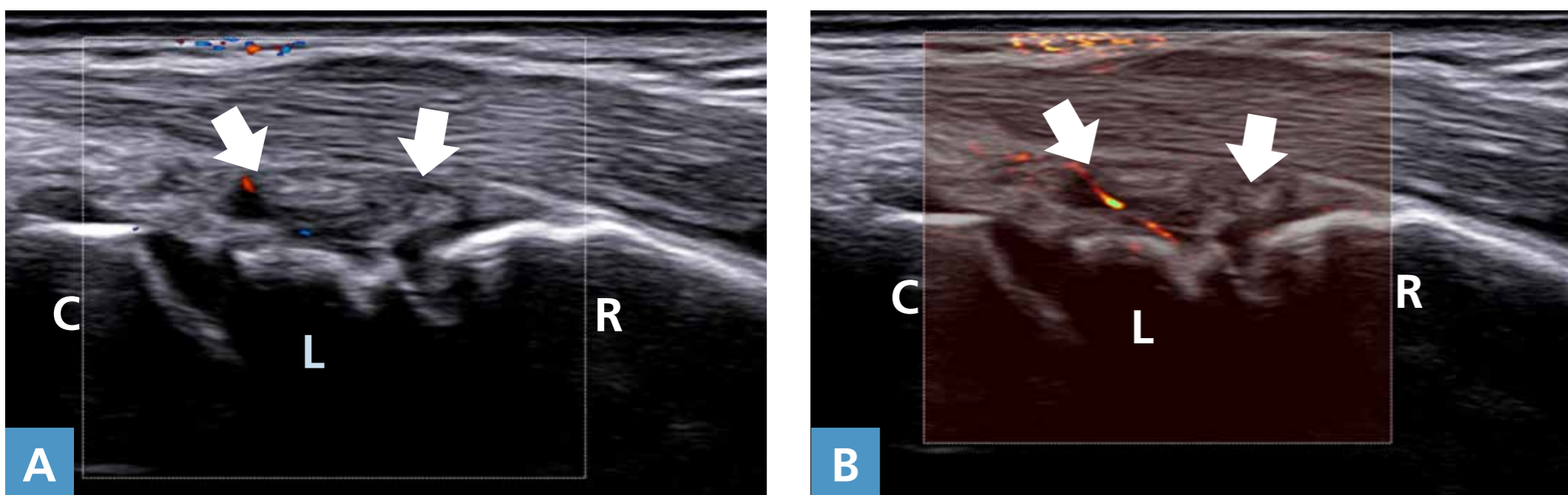
Conventional Color and Power Doppler tools may be suboptimal in the detection of microvasculature, due to the presence of strong wall filters which limit both the presence of artifacts and the visibility of very low flows.

microV may help to enhance the visibility of microcirculation.

Case 1

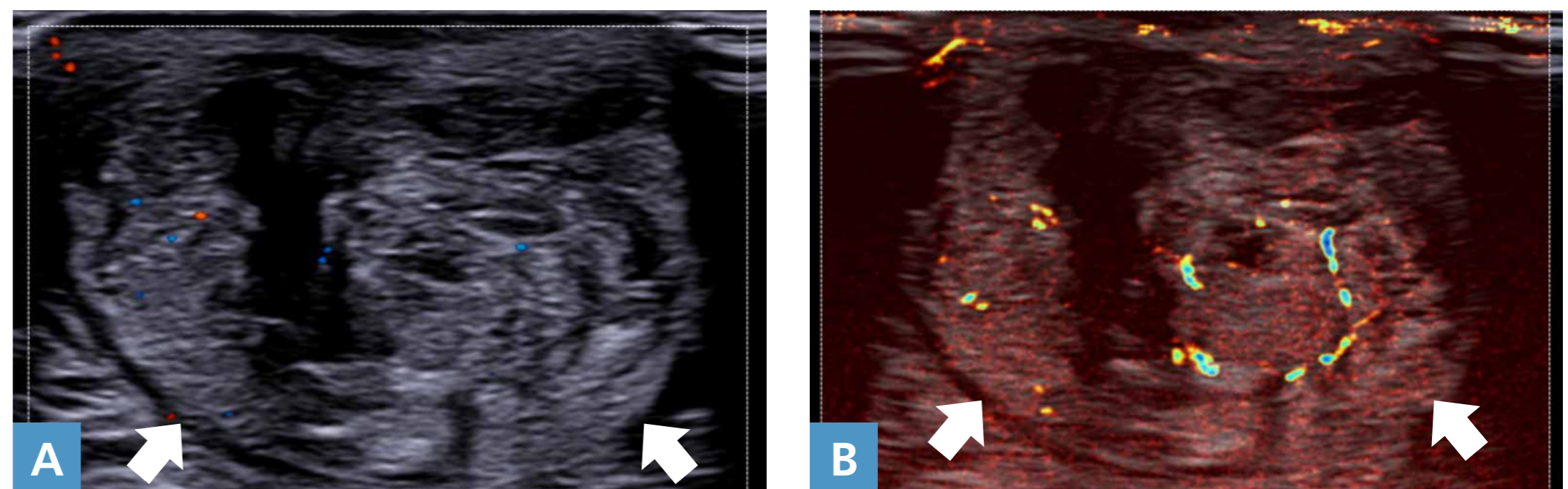
Forty-year-old male with suspected inflammatory arthritis of the wrist. The longitudinal scan over the dorsal aspect of the wrist shows a tiny synovial nodule (arrows). *microV* (panel B) improves the visibility of intrasynovial vascularization over conventional Power Doppler (panel A).

- R radius
- L lunate
- C capitate



Case 2

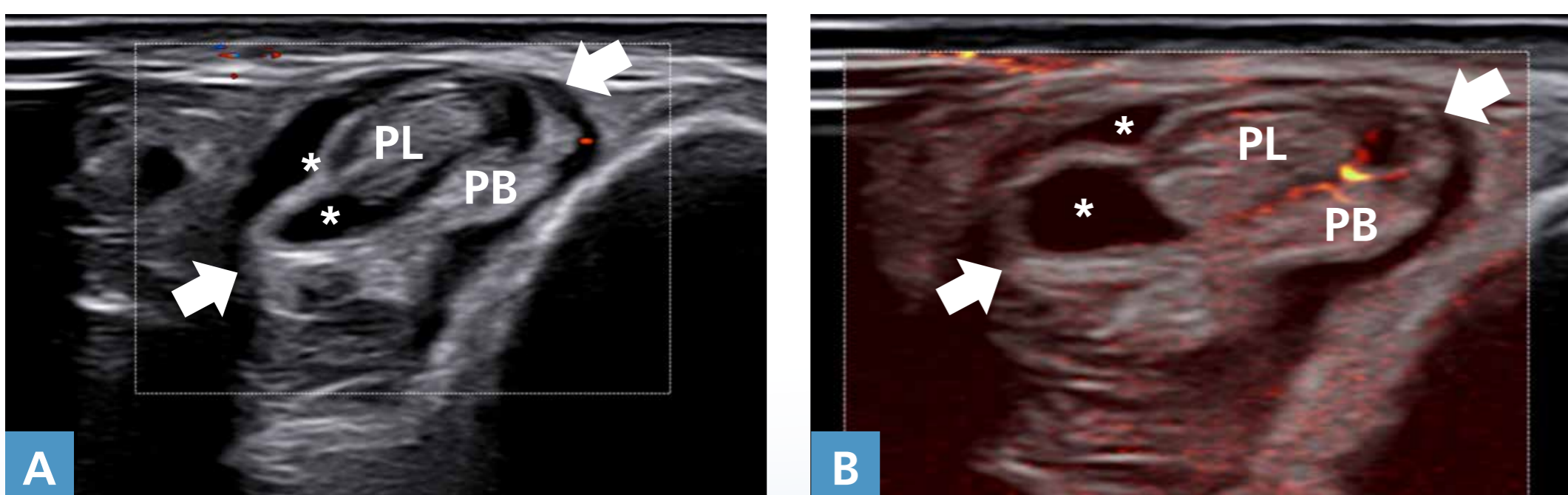
Sixty-one-year-old male with postoperative Achilles tendinopathy. A short-axis scan over the middle third of the tendon (arrows) shows remarkable thickening and inhomogeneity of the tendon matrix. *microV* (panel B) improves the visibility of intratendinous vascularization over conventional Power Doppler (panel A).



Case 3

Thirty-three-year-old male with degenerative peroneal tendinopathy. Peroneal tendons are swelling (arrows), with fluid distending the synovial sheath (asterisks). *microV* (panel B) improves the visibility of intratendinous vascularization over conventional Power Doppler (panel A).

- PL peroneus longus tendon
- PB peroneus brevis tendon



Case 4

Forty-three-year-old female with degenerative Achilles tendinopathy. The tendon (arrows) is thickened and inhomogeneous, with loss of normal fibrillar echotexture. *microV* (panel B) improves the visibility of intratendinous vascularization over conventional Power Doppler (panel A).

- C calcaneus

